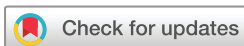

Changing faces of mitochondrial disease: autosomal recessive *POLG* disease mimicking myasthenia gravis and progressive supranuclear palsy

Menatalla Elwan,¹ Andrew M Schaefer,^{1,2} Kate Craig,² Sila Hopton,² Gavin Falkous,² Emma L Blakely,² Robert W Taylor,^{2,3} Naomi Warren¹

To cite: Elwan M, Schaefer AM, Craig K, *et al.* Changing faces of mitochondrial disease: autosomal recessive *POLG* disease mimicking myasthenia gravis and progressive supranuclear palsy. *BMJ Neurology Open* 2022;4:e000352. doi:10.1136/bmjno-2022-000352

Accepted 22 November 2022



© Author(s) (or their employer(s)) 2022. Re-use permitted under CC BY-NC. No commercial re-use. See rights and permissions. Published by BMJ.

¹Department of Neurology, Royal Victoria Infirmary, Newcastle upon Tyne, UK

²Wellcome Centre for Mitochondrial Research, Translational and Clinical Research Institute, Faculty of Medical Sciences, Newcastle University, Newcastle Upon Tyne, UK

³NHS Highly Specialised Service for Rare Mitochondrial Disorders, Newcastle University, Newcastle upon Tyne, UK

Correspondence to

Dr Naomi Warren;
naomiwarren@nhs.net

ABSTRACT

Background Mitochondrial disorders are known to cause diverse neurological phenotypes which cause a diagnostic challenge to most neurologists. Pathogenic polymerase gamma (*POLG*) variants have been described as a cause of chronic progressive external ophthalmoplegia, which manifests with ptosis, horizontal and vertical eye movement restriction and myopathy. Autosomal dominant progressive external ophthalmoplegia is rarely associated with Parkinsonism responsive to levodopa.

Methods We report a case of a 58-year-old man who presented with an eye movement disorder then Parkinsonism who made his way through the myasthenia then the movement disorder clinic.

Results A diagnostic right tibialis anterior biopsy revealed classical hallmarks of mitochondrial disease, and genetic testing identified compound heterozygous pathogenic gene variants in the *POLG* gene. The patient was diagnosed with autosomal recessive *POLG* disease.

Conclusions It is important to maintain a high index of suspicion of pathogenic *POLG* variants in patients presenting with atypical Parkinsonism and ophthalmoplegia. Patients with *POLG*-related disease will usually have ptosis, and downgaze is typically preserved until late in the disease. Accurate diagnosis is essential for appropriate prognosis and genetic counselling.

INTRODUCTION

Primary mitochondrial diseases are defined as disorders impacting the structure or function of the mitochondria as a result of pathogenic variants in either nuclear DNA (nDNA) or mitochondrial DNA (mtDNA).¹ Mitochondrial DNA polymerase gamma (*POLG*) is the enzyme responsible for mtDNA replication. *POLG* is encoded by the *POLG* gene, one of several nuclear-encoded genes implicated in mtDNA maintenance that can cause autosomal dominant or recessive mitochondrial genetic disease.² Mutations in *POLG* can cause early childhood mtDNA depletion syndromes or later-onset syndromes arising from mtDNA deletions.³ *POLG*-related disorders comprise a continuum of overlapping phenotypes

including progressive external ophthalmoplegia (PEO).⁴ Ptosis and proximal weakness are often present, and some patients with PEO phenotype are occasionally misdiagnosed as other conditions such as seronegative myasthenia gravis (MG).⁵

Other features of PEO may include cerebellar ataxia, neuropathy with proprioceptive loss and dysarthria.⁶ Parkinsonism is the most frequently observed extrapyramidal movement disorder in patients with *POLG* mutations and is associated initially with asymmetrical clinical and imaging features and good response to levodopa.³ Here, we present an unusual case of a 58-year-old man presenting with an eye movement disorder then Parkinsonism who was later discovered to have autosomal recessive *POLG* disease.

CASE PRESENTATION

A 58-year-old right-handed man was seen in the general neurology clinic in August 2016. He reported a 7-month history of painless left ptosis, worsening as the day progressed and intermittent diplopia. He also reported long-standing numbness and tingling of the hands and feet due to a known diabetic neuropathy. His balance was worsening, but had been poor for several years, requiring bannisters and handrails at home. He had a past medical history of type 1 diabetes mellitus, diagnosed at age 25. He was known to have a sensory axonal neuropathy, a diabetic retinopathy and bilateral cataracts (right cataract surgically removed in 2015). On examination, pupils were equal and reactive and he had full visual fields. He had fatigable partial left sided ptosis with restriction of horizontal eye movements and upgaze, but spared downgaze. Facial movements were reduced, interpreted as

mild bifacial weakness. Neck flexion and extension was medical research council (MRC) 5/5. Upper and lower limbs were of normal tone and power with no fatigable weakness. Reflexes were normal in the upper limbs but absent in the lower limbs. He had reduced pinprick sensation in the feet.

A provisional diagnosis of MG was made based on fatigable ptosis and diplopia and the patient was referred for single-fibre electromyography (EMG). Unfortunately, this was poorly tolerated and therefore only 14 single-fibre action potential pairs were acquired. However, two pairs showed borderline jitter and two showed pathological jitter. This was felt to be supportive of a diagnosis of MG. He also had nerve conduction studies, which revealed evidence of a significant axonal sensory neuropathy, consistent with the known history of diabetes.

He was started on trial of pyridostigmine 60 mg two times per day and bloods were sent for acetylcholine receptor antibodies, MuSK antibodies, LRP4 and low affinity antibodies which were all negative.

A CT scan of the chest showed no evidence of a thymoma. An MRI scan of the orbits showed slightly thinned optic nerves but no abnormal signal changes.

Three months later, the patient attended a routine follow-up. He reported no improvement in the ptosis or diplopia following initiation of pyridostigmine. He reported coughing with solid food and frequent nasal regurgitation to liquids. He had recurrent falls due to imbalance and he found fine dexterous tasks difficult that his wife had to help him with buttons and fastening shoelaces. Direct questioning revealed that he can be restless and can talk in his sleep but there was no suggestion of cognitive impairment. His examination was largely unchanged, but mild bradykinesia in the left upper limb was detected. A dopamine transporter (DaT) scan was performed which showed very poor uptake throughout the striata in keeping with an underlying Parkinsonian syndrome resulting from nigrostriatal dopaminergic deficiency. The patient was referred to the movement disorder clinic.

In March 2017, the patient was seen in the movement disorder clinic. He reported a number of falls, reduced volume speech and some choking episodes. Neurological examination was as above, in addition to slow, unsteady gait with bilateral reduced arm swing and bradykinesia, axial rigidity and moderate hypomimia. He had evidence of square wave jerks, restricted horizontal and up gaze with normal down gaze and hypometric slow saccades. The eye movements did not correct with doll's eye reflex. He had asymmetric Parkinsonism and negative sign d'aplaude. There was no palatal tremor, apraxia, facial dyskinesias or cerebellar ataxia. A diagnosis of possible progressive supranuclear palsy (PSP) was proposed and the patient was started on levodopa.

Due to paucity of concrete evidence pointing towards a diagnosis of ocular MG a repeat EMG was performed. This demonstrated no evidence of a significant defect of neuromuscular transmission in the muscles examined

including left orbicularis oculi. Pyridostigmine was stopped.

Three months later, the patient was seen by speech and language therapy and started on thickened fluids due to recurrent aspiration pneumonias. At clinic review, he reported subjective improvement in cognition and movement following commencement of levodopa. He was followed up in the atypical Parkinsonism clinic.

Over the next 2 years, he developed restless leg syndrome, poor short term memory, orthostatic hypotension, sialorrhoea and erectile dysfunction. He had ongoing problems with fine manual dexterity but less falls and he remained independently mobile. Examination including eye movements and gait remained unchanged over at least 2.5 years.

Due to the lack of progression, the presence of ptosis and preserved down-gaze, all of which are unusual in PSP, the patient was referred to the Highly Specialised Service for Rare Mitochondrial Disorders in Newcastle upon Tyne. Mild bilateral ptosis, a complex ophthalmoplegia and a relatively symmetric rigid akinetic syndrome were noted. There was no frontalis overactivity or significant cognitive deficit (Addenbrooke's Cognitive Examination -Revised 90/100). The presence of cataracts and axonal neuropathy raised the suspicion towards *POLG*-related disease. A diagnostic right tibialis anterior muscle biopsy revealed an excess of cytochrome *c* oxidase deficiency (affecting ~10% of all fibres) and evidence of subsarcolemmal mitochondrial accumulation (figure 1A); quadruple oxidative phosphorylation immunohistochemistry⁴ demonstrated respiratory chain deficiencies involving both complex I and complex IV (figure 1B). Interestingly, long range PCR of muscle DNA failed to document evidence of multiple mtDNA rearrangements (figure 1C). MtDNA copy number was normal. Next-generating sequencing analysis of 18 genes associated with disorders of mtDNA maintenance revealed two heterozygous *POLG* gene variants (NM_002693.2: c.2209G>A p.(Gly737Arg) and c.3287G>A p.(Arg1096His)) both of which have been associated with autosomal recessive *POLG* disease. Familial segregation studies to establish the phase of both variants confirmed they were on different alleles.

DISCUSSION

A review of the literature for pathogenic *POLG* variants associated with Parkinsonism, suggests that Parkinsonism occurred as a late complication of *POLG* mutations.⁷⁻¹¹ In one case a female patient presented with early onset Parkinsonism followed by PEO 7 years later.¹² Parkinsonism is reported to be associated with autosomal dominant PEO and there are limited reports of Parkinsonism associated with autosomal recessive *POLG* disease.¹³ As far as we are aware, no previous cases of *POLG* pathogenic variants have presented mimicking PSP. In all cases of Parkinsonism associated with *POLG* pathogenic variants, the patients had a positive DaT scan with reduced striatal

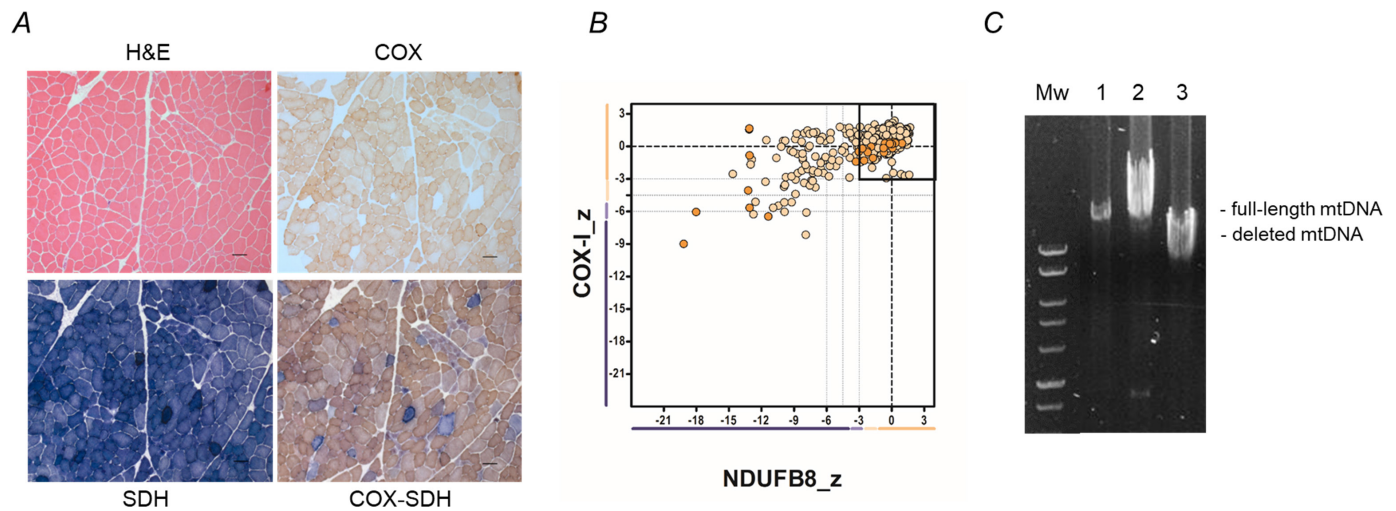


Figure 1 Histopathological and molecular genetic studies. (A) H&E staining, cytochrome c oxidase (COX) histochemistry, succinate dehydrogenase (SDH) histochemistry and sequential COX-SDH histochemistry demonstrate a clear mosaic pattern of COX deficiency with several fibres showing abnormal, subsarcolemmal accumulation of mitochondria. Scale bar=100µm. (B) Quadruple immunofluorescence analysis of NDUFB8 (complex I) and COXI (Complex IV) protein expression in patient muscle. Each dot represents the measurement from an individual muscle fibre, colour co-ordinated according to its mitochondrial mass (low=blue, normal=beige, high=orange, very high=red). Grey dashed lines represent SD limits for classification of the fibres. Lines next to x-axis and y-axis represent the levels of NDUFB8 and COXI: beige=normal (>−3), light beige=intermediate positive (−3 to −4.5), light purple=intermediate negative (−4.5 to −6), purple=deficient (< −6). Bold dashed lines represent the mean expression level of normal fibres. These data confirm a loss of NDUFB8 subunit expression in many fibres, and to a lesser extent COX1 expression, consistent with a multiple mitochondrial biochemical defect consistent with recessive *POLG* variants. (C) Long range PCR amplification of patient muscle DNA across the major arc shows no major evidence of multiple mtDNA deletions. Mw, molecular weight markers; lane 1, patient muscle; lane 2, control muscle; lane 3, muscle from a patient with a single, large-scale mtDNA rearrangement.

uptake bilaterally. They were also noted to have a good response to levodopa.

PSP is a rapidly progressive neurodegenerative disease with the leading feature of falls and a vertical supranuclear gaze palsy with nerve cell degeneration mainly in the brain stem. There are eight phenotypic variants of PSP and the combination of early onset postural instability and falls with vertical ocular motor dysfunction is referred to as Richardson's syndrome (PSP-RS).¹⁴ Parkinsonism resembling idiopathic Parkinson's disease (PSP-P) is another variant of PSP characterised by asymmetric onset, tremor and moderate response to levodopa. The mean age of onset of PSP-RS is 66 years with a disease duration of 7 years.¹⁵ There are rarer phenotypes as well as outlined in the MDS classification.¹⁴

As presented in our case, mitochondrial diseases present a challenge in diagnosis due to their highly diverse presentations. Our patient's presentation originally mimicked MG due to the presence of ptosis, complex ophthalmoplegia and the presence of pathological jitter on the initial EMG. When the Parkinsonism symptoms emerged, the diagnosis was revised to PSP. It was, however, atypical from the outset due to ptosis, early involvement of horizontal eye movements with preserved down gaze and later due to the limited progression over time.

Autosomal recessive *POLG*-related disorders can present in infancy to early childhood with severe fatal

phenotypes such as Alpers-Huttenlocher syndrome and childhood myocerebrohepatopathy spectrum. In adulthood, the syndromes are less severe and are not associated with systemic involvement such as in ataxia neuropathy spectrum, arPEO and adPEO.⁴ Our patient's phenotype resembles adPEO given the presence of Parkinsonism, axonal neuropathy and cataracts.

Although unusual, it is important to maintain a high index of suspicion of pathogenic *POLG* variants in patients presenting with atypical Parkinsonism and ophthalmoplegia. Patients with PSP usually progress between appointments and absence of progression should spark a review of the diagnosis. Patients with *POLG*-related disease will usually have ptosis, and down-gaze is typically preserved until late in the disease. Accurate diagnosis is essential for appropriate prognosis and genetic counselling. These patients also tend to have a good response to dopaminergic medications.

Contributors AMS, RWT and NW planned the study. NW and AMS assessed the patient in an outpatient setting, and collected the clinical data. KC, SH, GF and ELB undertook the laboratory studies, supervised by RWT. RWT obtained funding for the laboratory studies. ME, AMS, RWT and NW wrote the first draft of the manuscript. All authors contributed to the critical revision of the text prior to submission.

Funding RWT is funded by the Wellcome Centre for Mitochondrial Research (203105/Z/16/Z), the Mitochondrial Disease Patient Cohort (UK) (G0800674), the Medical Research Council International Centre for Genomic Medicine in Neuromuscular Disease (MR/S005021/1), the Medical Research Council (MR/W019027/1), the Lily Foundation, the Pathological Society, the UK NIHR Biomedical Research Centre for Ageing and Age-related disease award to the Newcastle upon

Tyne Foundation Hospitals NHS Trust and the UK NHS Highly Specialised Service for Rare Mitochondrial Disorders of Adults and Children.

Competing interests None declared.

Patient consent for publication Not applicable.

Provenance and peer review Not commissioned; externally peer reviewed.

Data availability statement All data created during this research are openly available at doi:10.1136/bmjno-2022-000352

Open access This is an open access article distributed in accordance with the Creative Commons Attribution Non Commercial (CC BY-NC 4.0) license, which permits others to distribute, remix, adapt, build upon this work non-commercially, and license their derivative works on different terms, provided the original work is properly cited, appropriate credit is given, any changes made indicated, and the use is non-commercial. See: <http://creativecommons.org/licenses/by-nc/4.0/>.

REFERENCES

- 1 Parikh S, Goldstein A, Koenig MK, *et al*. Diagnosis and management of mitochondrial disease: a consensus statement from the mitochondrial medicine Society. *Genet Med* 2015;17:689–701.
- 2 Van Goethem G, Schwartz M, Löfgren A, *et al*. Novel POLG mutations in progressive external ophthalmoplegia mimicking mitochondrial neurogastrointestinal encephalomyopathy. *Eur J Hum Genet* 2003;11:547–9.
- 3 Rahman S, Copeland WC. Polg-related disorders and their neurological manifestations. *Nat Rev Neurol* 2019;15:40–52.
- 4 Cohen BH, Chinnery PF, Copeland WC. POLG-related disorders. In: Adam MP, Everman DB, Mirzaa GM, *et al*, eds. *Gene reviews*. Seattle (WA): University of Washington, 1993–2022, 2010. <https://www.ncbi.nlm.nih.gov/books/>
- 5 YS N, Turnbull DM. Mitochondrial disease: genetics and management. *J Neurol* 2016;263:179–91.
- 6 Stumpf JD, Saneto RP, Copeland WC. Clinical and molecular features of POLG-related mitochondrial disease. *Cold Spring Harb Perspect Biol* 2013;5:a011395.
- 7 Ahmed ST, Alston CL, Hopton S, *et al*. Using a quantitative quadruple immunofluorescent assay to diagnose isolated mitochondrial complex I deficiency. *Sci Rep* 2017;7:15676.
- 8 Miguel R, Gago MF, Martins J, *et al*. POLG1-related levodopa-responsive parkinsonism. *Clin Neurol Neurosurg* 2014;126:47–54.
- 9 Bandettini di Poggio M, Nesti C, Bruno C, *et al*. Dopamine-agonist responsive Parkinsonism in a patient with the SANDO syndrome caused by POLG mutation. *BMC Med Genet* 2013;14:105.
- 10 Dolhun R, Presant EM, Hedera P. Novel polymerase gamma (POLG1) gene mutation in the linker domain associated with parkinsonism. *BMC Neurol* 2013;13:92.
- 11 Sato K, Yabe I, Yaguchi H, *et al*. Genetic analysis of two Japanese families with progressive external ophthalmoplegia and parkinsonism. *J Neurol* 2011;258:1327–32.
- 12 Ma L, Mao W, Xu E, *et al*. Novel POLG mutation in a patient with early-onset parkinsonism, progressive external ophthalmoplegia and optic atrophy. *Int J Neurosci* 2020;130:319–21.
- 13 Davidzon G, Greene P, Mancuso M, *et al*. Early-onset familial parkinsonism due to POLG mutations. *Ann Neurol* 2006;59:859–62.
- 14 Höglinger GU, Respondek G, Stamelou M. Movement disorder Society-endorsed PSP Study Group. Clinical diagnosis of progressive supranuclear palsy: the movement disorder society criteria. *Mov Disord* 2017;32:853–64.
- 15 Williams DR, de Silva R, Paviour DC, *et al*. Characteristics of two distinct clinical phenotypes in pathologically proven progressive supranuclear palsy: Richardson's syndrome and PSP-parkinsonism. *Brain* 2005;128:1247–58.