


# Opsoclonus myoclonus ataxia syndrome, ovarian teratoma and anti-NMDAR antibody: an 'unresolved' mystery

Angel T Miraclin,<sup>1</sup> Arun Mathai Mani,<sup>1</sup> Ajith Sivadasan,<sup>1</sup> Aditya Nair,<sup>1</sup> Munagapati Christina,<sup>2</sup> Abigail Ruth Gojer,<sup>2</sup> Sharon Milton,<sup>3</sup> John A Jude Prakash,<sup>4</sup> Rohit N Benjamin,<sup>1</sup> Appaswamy Thirumal Prabhakar ,<sup>1</sup> Vivek Mathew,<sup>1</sup> Sanjith Aaron<sup>1</sup>

**To cite:** Miraclin AT, Mani AM, Sivadasan A, *et al.* Opsoclonus myoclonus ataxia syndrome, ovarian teratoma and anti-NMDAR antibody: an 'unresolved' mystery. *BMJ Neurology Open* 2023;5:e000414. doi:10.1136/bmjno-2023-000414

Accepted 20 May 2023

## ABSTRACT

**Background** Opsoclonus–myoclonus–ataxia syndrome (OMAS) is characterised by the combination of opsoclonus and arrhythmic action myoclonus with axial ataxia and dysarthria. In adults, a majority are paraneoplastic secondary to solid organ tumours and could harbour antibodies against intracellular epitopes; however, certain proportions have detectable antibodies to various neuronal cell surface antigens. Anti-N-methyl-D-aspartate (NMDAR) antibodies and ovarian teratomas have been implicated in OMAS.

**Methods** Report of two cases and review of literature.

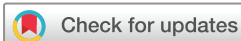**Results** Two middle-aged women presented with subacute-onset, rapidly progressive OMAS and behavioural changes consistent with psychosis. The first patient had detectable antibodies to NMDAR in the cerebrospinal fluid (CSF) alone. Evaluation for ovarian teratoma was negative. The second patient had no detectable antibodies in serum or CSF; however, she had an underlying ovarian teratoma. Patient A was treated with pulse steroids, therapeutic plasma exchange (TPE) followed by bortezomib (BOR) and dexamethasone, while patient B was treated with steroids, TPE followed by surgical resection of ovarian teratoma. Both patients had favourable outcomes and were asymptomatic at the 6 monthly follow-up.

**Conclusions** With coexistent neuropsychiatric manifestations, OMAS can be considered a distinct entity of autoimmune encephalitis, pathogenesis being immune activation against known/unknown neuronal cell surface antigens. The observation of absence of anti-NMDAR antibody in patients with teratoma-associated OMAS and vice versa is intriguing. Further research on the potential role of ovarian teratoma in evoking neuronal autoimmunity and its targets is required. The management challenge in both cases including the potential use of BOR has been highlighted.

## INTRODUCTION

Opsoclonus–myoclonus–ataxia syndrome (OMAS) is a unique presentation of neurological disorders characterised by (1) opsoclonus (chaotic, conjugate and rapid

involuntary eye movements without intersaccadic interval); (2) myoclonus (sudden jerky movements involving the axial and limb musculature; and (3) ataxia (appendicular and axial of varying severity). It is common in children than adults. In adults, after excluding structural lesions, the most common aetiologies include parainfectious (*Salmonella*, Coxsackie B3 virus, HIV, Epstein-Barr virus, St. Louis encephalitis, falciparum malaria and scrub typhus) or paraneoplastic (carcinoma of the lung and breast, ovarian teratomas (mature or immature), renal cell cancers and pancreatic malignancies) causes, of which the paraneoplastic aetiology amounts to 60% of the cases.<sup>1 2</sup> Regarding the pathogenesis, there are two major observations: (1) disinhibition of the fastigial nucleus, which is supported by the functional MRI studies on patients with OMAS in comparison with health subjects, and (2) immune hypothesis, where a proportion of these patients have identifiable antibodies against neuronal cell surface antigens and neurofilament antigens.<sup>2–5</sup> However, research had failed to reveal a common neural antigen causing this unique presentation. Pranzatelli *et al* were able to demonstrate increased titres of CD19+ B cells among those children with neuroblastoma-associated paraneoplastic OMAS, and these children had a favourable response to B-cell depletion therapies.<sup>6 7</sup> Overall, this entity could be considered in the spectrum of autoimmune (brainstem) encephalitis, with good response to immunotherapy and removal of neoplasm.<sup>1 8 9</sup> Here we report two young women presenting with subacute-onset OMAS with psychiatric manifestations and seizures. We aim to highlight



© Author(s) (or their employer(s)) 2023. Re-use permitted under CC BY-NC. No commercial re-use. See rights and permissions. Published by BMJ.

<sup>1</sup>Department of Neurosciences, Christian Medical College Vellore, Vellore, Tamil Nadu, India

<sup>2</sup>Department of Psychiatry, Christian Medical College Vellore, Vellore, Tamil Nadu, India

<sup>3</sup>Department of Clinical Pathology, Christian Medical College Vellore, Vellore, Tamil Nadu, India

<sup>4</sup>Department of Clinical Microbiology, Christian Medical College Vellore, Vellore, Tamil Nadu, India

## Correspondence to

Dr Ajith Sivadasan; [ajiths@cmcvellore.ac.in](mailto:ajiths@cmcvellore.ac.in)

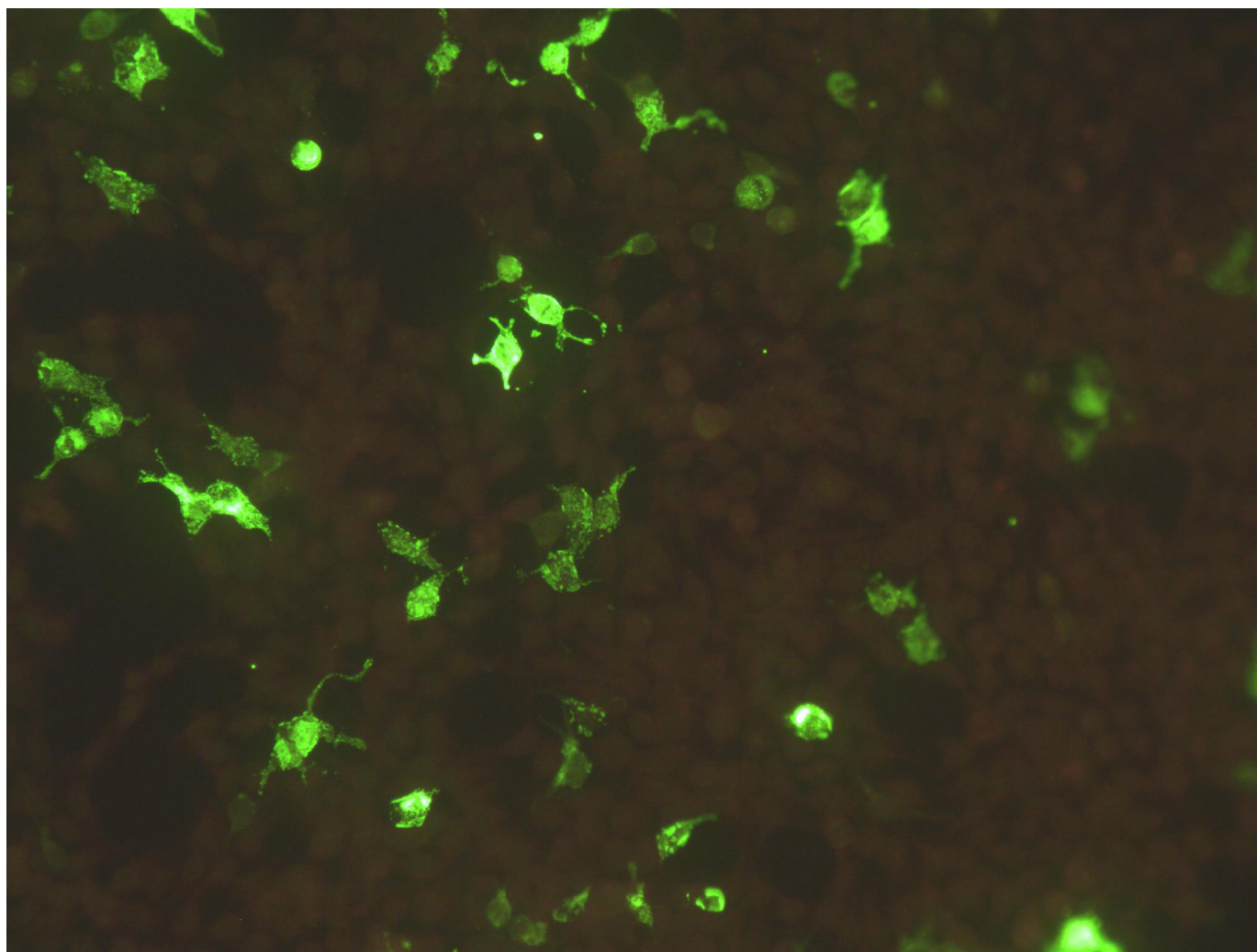
a few interesting observations regarding the diagnostic workup and treatment in these patients.

## CASE REPORT

### Patient A

A 29-year-old woman presented with a 9-week history of ataxia with involuntary jerky movements of the eyes and trunk with behavioural disturbances in the form of increased fearfulness, anger outburst and violent behaviour towards her mother and husband. She had a history of acute onset of ataxia, about 3 years ago, which occurred immediately post partum and was managed as postinfectious cerebellitis with corticosteroids, with which she had complete clinical recovery. Clinical examination revealed that the patient had bilateral opsoclonus and action myoclonus with truncal and appendicular ataxia. She had bilateral dysdiadochokinesia with dysmetria with wide-based ataxic gait. Clinical features were consistent with OMAS and coexistent neuropsychiatric

manifestations. Her MRI of the brain with contrast did not reveal any structural lesions. Her cerebrospinal fluid (CSF) studies showed four cells, all lymphocytes with elevated protein (protein 50 mg/dL and glucose 73 mg/dL). Autoimmune (including thyroid antibodies) and metabolic workup were negative. In view of the history of steroid-responsive cerebellar syndrome, a likely inflammatory aetiology was considered. She was initiated on pulse doses of methyl prednisolone (1000 mg intravenous methyl prednisolone for 5 days). Over the period of next 1 week, her behavioural disturbances worsened with severe agitation, hallucinations and violent behaviour, which were unresponsive to escalating doses of antipsychotics and benzodiazepines. On day 8, her autoantibody for NMDA receptor was reported positive in CSF ([figure 1](#)), with the corresponding serum sample being negative. Serum onconeural antibody profile (Euroimmune IgG, Lubeck, Germany; panel includes anti-Hu, Yo, CV2, Ri, Ma2, amphiphysin, SOX1, Tr, Recoverin, Zic4,

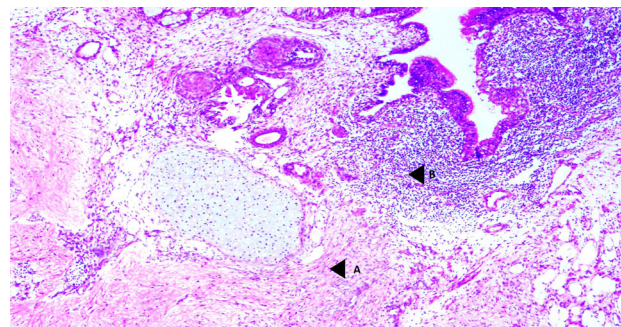


**Figure 1** Cell-based assay using human embryonic kidney cells expressing GluN1 subunits of NMDAR. Undiluted CSF was tested as per manufacturer instructions (Euroimmune Ag, Lubeck, Germany). We classify the assay as strong positive when there is fluorescence signal which is >2+ intensity (ie, more than the intensity of the positive control given in the kit). CSF, cerebrospinal fluid; NMDAR, N-methyl-D-aspartate.

Titin and GAD65) was negative. Oncological evaluation with full-body positron emission tomography (PET) scan and pelvic ultrasound was negative for any neoplasm, specifically ovarian teratoma. Rituximab (RTX) infusion was planned; however, she developed an allergic reaction to the test dose. Neuropsychiatric manifestations continued to worsen, and she progressed to develop encephalopathy. TPE (under controlled sedation) was initiated following which mild stabilisation in clinical condition was noted. However, she continued to have OMAS and psychosis. Based on existing reports on the use of bortezomib (BOR) for refractory autoimmune (anti-N-methyl-D-aspartate (NMDAR)) encephalitis,<sup>10–12</sup> it was decided to treat her with the regimen of subcutaneous BOR (1.3 mg/m<sup>2</sup>) and dexamethasone (20 mg) given on days 1, 4, 8 and 11 followed by 10 days of drug-free interval. The first cycle was started on hospitalisation day 18. Following initiation of BOR, she had remarkable recovery in the form of near-complete resolution of opsoclonus, myoclonus and ataxia. Her agitation, restlessness and impulsivity reduced, and her antipsychotic doses were gradually decreased. BOR was stopped after two cycles and steroid doses were tapered and stopped. She was discharged after 34 days of hospitalisation and was largely asymptomatic with minor behavioural issues at 3 and 6 month follow-ups. She was well for 2 years and succumbed in the delta wave of the COVID-19 pandemic in 2021.

### Patient B

A 28-year-old woman presented with a 10-week history of gait ataxia with involuntary movements of the body, diplopia with oscillopsia and seizures. She had developed new-onset behavioural changes with decreased interaction with family members, decreased sleep and anhedonia. She progressed to develop slurring of speech with cough on oral intake with nasal regurgitation. Clinical examination revealed her to be agitated and restless, with generalised tremors and action myoclonus. Cranial nerve examination revealed opsoclonus with decreased palatal movements bilaterally and decreased gag reflex bilaterally. Motor system examination showed generalised dystonia with rigidity with Medical Research Council (MRC) grade 4/5 power in bilateral upper limbs and lower limbs. She had generalised hyper-reflexia with pendular knee jerk. She had bilateral cerebellar signs in the form of dysmetria, dysdiadochokinesia and impaired tandem walk. Her gait was wide-based ataxic, requiring assistance for ambulation. MRI of the brain with contrast did not reveal any structural lesions. CSF analysis showed normal cell counts with elevated protein (67 mg/dL). On day 6 of hospitalisation, autoimmune encephalitis panel and onconeural antibodies panel in serum and CSF were negative. Oncological evaluation with whole-body PET scan identified a right ovarian neoplasm. She progressed to develop worsening of opsoclonus, tremors and myoclonus with behavioural disturbances in the form of agitation and hence was transferred to the high-dependency



**Figure 2** H&E section of right ovarian cyst showing mature cystic teratoma at  $\times 40$  magnification. Cyst is lined mainly by columnar epithelium. The stroma shows mature cartilage, mature nervous tissue inciting a lymphocytic response and with no abnormal dystrophic neurons, lobules of mature adipocytes, smooth muscle bundles and lymphoid aggregates. A, neural tissue with no abnormal dystrophic neurons; B, lymphocytic response to neural tissue.

unit. She was initiated on TPE on day 10 of hospitalisation. She had five sessions of TPE followed by pulse intravenous methyl prednisolone (1000 mg once daily for 5 days). She was taken up post clinical stabilisation for right salpingo-oophorectomy. A 6 $\times$ 6 cm right ovarian cyst with solid component was removed and histopathology was consistent with mature cystic teratoma (figure 2), which showed the presence of mature neural elements surrounded by dense inflammatory infiltrates. Postoperatively, she had dramatic clinical recovery with near-complete resolution of opsoclonus and ataxia. Steroids were gradually tapered and stopped. RTX was administered due to initial reservations about the possibility of a relapse. She was asymptomatic at the follow-ups of 3 and 6 months. Further immunotherapy was not continued, and at 2 years of follow-up, she reported being normal and independent for all activities of daily living.

### DISCUSSION

These two cases highlight few interesting observations. Both patients had OMAS and prominent neuropsychiatric manifestations. CSF anti-NMDAR antibody was positive in the first patient who did not have a teratoma, and the second patient had a teratoma without any demonstrable antibodies. Management in both cases was challenging in view of the progression and coexistent psychosis despite high doses of antipsychotic agents. The planning of surgical removal of teratoma is challenging and often has to be prompt despite the severity of the illness.<sup>13</sup> We were especially concerned with use of pulse steroids in the setting of psychosis. Both patients had good outcome with a multimodality treatment approach including judicious use of steroids, TPE (under controlled sedation), immunosuppressants (BOR and RTX) and tumour removal (patient B).

Anti-NMDAR encephalitis presenting as a brainstem cerebellar syndrome such as OMAS is a rarity. There are only a few case reports reported in literature

with antibody positivity and with clinical presentation as OMAS, among which one reported case is from the paediatric age group.<sup>14–17</sup> In a large cohort of patients with teratoma-associated encephalitis (211 patients), the novel presentation as brainstem–cerebellar syndrome with opsoclonus was seen in 58% of those who were negative for the anti-NMDAR antibodies (22 of 38 patients), with none in the antibody-positive group having a similar presentation.<sup>18</sup> The mechanism of occurrence of this brainstem–cerebellar syndrome appears to be due to the dysfunction of omnipause neurons in the brainstem (parapontine reticular formation) and involvement of the fastigial nucleus.<sup>2 3</sup> An unknown neuronal cell membrane-based antibody in conjunction with the anti-NMDAR antibody seems to be the most plausible explanation for this interesting observation.<sup>14 15</sup> One hypothesis implicated the pathogenic role of glycine receptor (GlyR) antibodies<sup>5 18 19</sup> in this scenario. Glycine is the chief neurotransmitter of the omnipause neurons, which in turn modulate the burst neurons initiating saccades. However, due to non-availability of the test in our centre, we could not test our hypothesis that this could be associated with OMAS. It is unlikely that the anti-NMDAR antibody is an epiphenomenon, considering the coexistent neuropsychiatric manifestations and the presence of antibodies in CSF. The outcomes of teratoma-associated OMAS are remarkable with immunotherapy, and almost 75% have complete recovery at a median follow-up of 15 months.<sup>14</sup>

The association of ovarian teratoma with NMDAR encephalitis is intriguing; not all teratomas potentially lead to development of autoimmune encephalitis (AIE). Dabner *et al* compared the histopathology of teratomas associated with anti-NMDAR encephalitis with sporadic control teratomas and showed prominent intratumoural lymphoid infiltrate closely clustered around the mature neuroglial elements.<sup>20</sup> They further hypothesise that this histology might be a harbinger to develop AIE, post resection of tumour. Presence of NR1 and NR2B receptor-positive neural elements and predominant CD4-positive lymphocytic infiltration has been independently associated with development of antibodies against NMDAR subunits and overt clinical disease.<sup>21</sup> It is interesting to note that neuroglial elements are integral parts of a teratoma and are present in 30%–50% of cases; however, not all cases with teratoma and neuroglial elements progress to develop AIE. In their study, Day *et al* have shown that presence of abnormal dysplastic neurons with binucleation or multinucleation, dysmorphism and inappropriate clustering appears to be the focus for immune sensitisation and breakdown of self-tolerance.<sup>22</sup> It is also worthwhile to note that the dense inflammatory response around the dysplastic/tumour-like neural elements in teratoma acts similarly to tertiary lymphoid organs producing antibodies in response to chronic inflammation caused by the persistent antigenic trigger.<sup>23</sup> Comparing this with our case, we do prove the presence of the mature

neuroglial elements and the inflammatory infiltrate around the neural elements in the teratoma.

We also report the good clinical improvement with BOR in the OMAS associated with anti-NMDAR encephalitis. BOR targets the antibody secreting plasma cells, making it a potential second-line therapy in those resistant to or in those with intolerance to RTX.<sup>24</sup> Considering the relatively quick onset of action, BOR can be considered as a potential therapeutic option in antibody-mediated neurological disorders. A synergistic effect with RTX could also be present.<sup>25</sup> Antimicrobial prophylaxis with acyclovir and cotrimoxazole is usually administered during BOR therapy. Long-term use of BOR is to be discouraged, considering risks of immunosuppression, reactivation of infections and dose-related peripheral neuropathy. The recovery in the second case was dramatic postsurgical resection, implying the auto-immune trigger to be the teratoma itself. Hence, there may not be a role for long-term immunotherapy in this scenario as observed in our case.

## CONCLUSIONS

Our cases highlight this novel presentation of brainstem–cerebellar syndrome (OMAS) among patients with treatment-responsive autoimmune encephalitis. It is to be noted that patients with teratoma-associated OMAS and coexistent neuropsychiatric manifestations are negative for the anti-NMDAR antibody, and those with the antibody and OMAS do not have a teratoma. This implies that a yet unidentified neuronal cell membrane (such as GlyR antibody)-directed antibody might be implicated in OMAS even in cases with anti-NMDAR antibody. Teratoma associated with anti-NMDAR antibody has unique histopathological characteristics and it functions as a tertiary lymphoid organ, causing break in immune self-tolerance. Judicious use of immunotherapy often translates into good clinical outcomes.

**Contributors** ATM and AS planned, conducted, drafted the manuscript and submitted the study. AMM, AN, MC and ARG contributed to the management of the patients and critically reviewed the manuscript. SM and JAJP contributed to the diagnostics and the images in the manuscript. RNB, ATP, VM and SA critically reviewed the manuscript.

**Funding** The authors have not declared a specific grant for this research from any funding agency in the public, commercial or not-for-profit sectors.

**Competing interests** None declared.

**Patient consent for publication** Consent obtained from parent(s)/guardian(s).

**Provenance and peer review** Not commissioned; externally peer reviewed.

**Data availability statement** Data are available upon reasonable request.

**Open access** This is an open access article distributed in accordance with the Creative Commons Attribution Non Commercial (CC BY-NC 4.0) license, which permits others to distribute, remix, adapt, build upon this work non-commercially, and license their derivative works on different terms, provided the original work is properly cited, appropriate credit is given, any changes made indicated, and the use is non-commercial. See: <http://creativecommons.org/licenses/by-nc/4.0/>.

## ORCID iD

Appaswamy Thirumal Prabhakar <http://orcid.org/0000-0003-2008-1808>

## REFERENCES

- 1 Sahu JK, Prasad K. The opsoclonus–myoclonus syndrome. *Pract Neurol* 2011;11:160–6.
- 2 Wong AM, Musallam S, Tomlinson RD, et al. Opsoclonus in three dimensions: oculo-graphic, neuropathologic and modelling correlates. *J Neurol Sci* 2001;189:71–81.
- 3 Zee DS, Robinson DA. A hypothetical explanation of saccadic oscillations. *Ann Neurol* 1979;5:405–14.
- 4 Sabater L, Xifró X, Saiz A, et al. Analysis of antibodies to neuronal surface antigens in adult opsoclonus-myoclonus. *J Neuroimmunol* 2008;196:188–91.
- 5 Armangué T, Sabater L, Torres-Vega E, et al. Clinical and immunological features of opsoclonus-myoclonus syndrome in the era of neuronal cell surface antibodies. *JAMA Neurol* 2016;73:417–24.
- 6 Pranzatelli MR, Travelstead AL, Tate ED, et al. B- and T-cell markers in Opsoclonus–myoclonus syndrome. *Neurology* 2004;62:1526–32.
- 7 Pranzatelli MR, Tate ED, Swan JA, et al. B cell depletion therapy for new-onset opsoclonus-myoclonus. *Mov Disord* 2010;25:238–42.
- 8 Arroyo HA, Tringler N. Opsoclonus-myoclonus syndrome. *Medicina (Mex)* 2009;69:64–70.
- 9 Oh S-Y, Kim J-S, Dieterich M. Update on opsoclonus-myoclonus syndrome in adults. *J Neurol* 2019;266:1541–8.
- 10 Scheibe F, Prüss H, Mengel AM, et al. Bortezomib for treatment of therapy-refractory anti-NMDA receptor encephalitis. *Neurology* 2017;88:366–70.
- 11 Shin Y-W, Lee S-T, Kim T-J, et al. Bortezomib treatment for severe refractory anti-NMDA receptor encephalitis. *Ann Clin Transl Neurol* 2018;5:598–605.
- 12 Turnbull MT, Siegel JL, Becker TL, et al. Early bortezomib therapy for refractory anti-NMDA receptor encephalitis. *Front Neurol* 2020;11:188.
- 13 Thiyagarajan M, Sebastian A, Thomas DS, et al. Ovarian teratoma and N-methyl-D-aspartate receptor autoimmune encephalitis: insights into imaging diagnosis of teratoma and timing of surgery. *J Clin Gynecol Obstet* 2021;10:22–7.
- 14 Armangue T, Titulaer MJ, Sabater L, et al. A novel treatment-responsive encephalitis with frequent opsoclonus and teratoma. *Ann Neurol* 2014;75:435–41.
- 15 Smith JH, Dhamija R, Moseley BD, et al. N-methyl-D-aspartate receptor autoimmune encephalitis presenting with opsoclonus-myoclonus: treatment response to plasmapheresis. *Arch Neurol* 2011;68:1069–72.
- 16 Kurian M, Lalive PH, Dalmau JO, et al. Opsoclonus-myoclonus syndrome in anti-N-methyl-D-aspartate receptor encephalitis. *Arch Neurol* 2010;67:118–21.
- 17 Player B, Harmelink M, Bordini B, et al. Pediatric opsoclonus-myoclonus-ataxia syndrome associated with anti-N-methyl-D-aspartate receptor encephalitis. *Pediatr Neurol* 2015;53:456–8.
- 18 Armangue T, Titulaer MJ, Sabater L, et al. A novel treatment-responsive encephalitis with frequent opsoclonus and Teratoma. *Ann Neurol* 2014;75:435–41.
- 19 Carvajal-González A, Leite MI, Waters P, et al. Glycine receptor antibodies in PERM and related syndromes: characteristics, clinical features and outcomes. *Brain* 2014;137:2178–92.
- 20 Dabner M, McCluggage WG, Bundell C, et al. Ovarian teratoma associated with anti-N-methyl D-aspartate receptor encephalitis: a report of 5 cases documenting prominent intratumoral lymphoid infiltrates. *Int J Gynecol Pathol* 2012;31:429–37.
- 21 Tabata E, Masuda M, Eriguchi M, et al. Immunopathological significance of ovarian teratoma in patients with anti-N-methyl-D-aspartate receptor encephalitis. *Eur Neurol* 2014;71:42–8.
- 22 Day GS, Laiq S, Tang-Wai DF, et al. Abnormal neurons in teratomas in NMDAR encephalitis. *JAMA Neurol* 2014;71:717–24.
- 23 Chefdeville A, Treilleux I, Mayeur M-E, et al. Immunopathological characterization of ovarian teratomas associated with anti-N-methyl-D-aspartate receptor encephalitis. *Acta Neuropathol Commun* 2019;7:38.
- 24 Frontiers. Early bortezomib therapy for refractory anti-NMDA receptor encephalitis. *Neurology*. Available: <https://www.frontiersin.org/articles/10.3389/fneur.2020.00188/full> [Accessed 3 Jul 2020].
- 25 Schneider-Gold C, Reinacher-Schick A, Ellrichmann G, et al. Bortezomib in severe MuSK-antibody positive myasthenia gravis: first clinical experience. *Ther Adv Neurol Disord* 2017;10:339–41.