

Dilated fixed pupils and respiratory failure: a rare clinical course of Lambert-Eaton myasthenic syndrome

Michelle FM ten Brinck , Inge WH Verheijen, Jaron van de Wardt, Gert W van Dijk, Frouke AP Nijhuis, Aad Verrips

To cite: ten Brinck MFM, Verheijen IWH, van de Wardt J, *et al.* Dilated fixed pupils and respiratory failure: a rare clinical course of Lambert-Eaton myasthenic syndrome. *BMJ Neurology Open* 2023;5:e000426. doi:10.1136/bmjno-2023-000426

► Additional supplemental material is published online only. To view, please visit the journal online (<http://dx.doi.org/10.1136/bmjno-2023-000426>).

Accepted 02 July 2023

ABSTRACT

Background Lambert-Eaton myasthenic syndrome (LEMS) is a neuromuscular junction disorder and the clinical triad consists of proximal muscle weakness, autonomic symptoms and reduced tendon reflexes. Sluggish pupillary reflexes are common but dilated fixed pupils are rare.

Case presentation We report a patient with a rare clinical course of LEMS. The patient was hospitalised due to progressive dyspnoea. She was ambulant and independent of oxygen at hospitalisation. The following day she suffered an in-hospital cardiac arrest based on hypoxia due to sputum stasis. The neurology department was consulted since the patient did not trigger on the ventilator after cessation of sedation. On neurological examination, the patient had dilated and fixed pupils, severe muscle weakness and areflexia, but a normal consciousness. Finally, she was diagnosed with LEMS. In this case report, the clinical course and diagnostic workup including anti-VGCC antibody testing, imaging and the results of electrophysiological studies are discussed. We also emphasise the importance of malignancy screening since the conventional chest CT was negative for lung carcinoma, but PET-CT raised a high suspicion for small-cell lung carcinoma.

Conclusions A rare course of LEMS, with early respiratory failure and wide, fixed pupils. Regarding repetitive nerve stimulation, it is important to stimulate long enough to see the incremental response. Furthermore, this study illustrated the importance of malignancy screening with PET-CT when there is a high suspicion of small-cell lung carcinoma with negative conventional CT.

INTRODUCTION

The clinical triad of Lambert-Eaton myasthenic syndrome (LEMS) consists of proximal muscle weakness, autonomic symptoms and reduced tendon reflexes. Presentation with severe respiratory failure has been described, although it is uncommon.^{1 2} Sluggish pupillary reflexes are common but dilated fixed pupils are rare.³ Additionally, articles regarding the differential diagnosis of bilateral mydriasis do usually not list LEMS.⁴⁻⁶

We present a case of a conscious patient with both respiratory failure and dilated fixed

pupils after cardiac resuscitation, ultimately diagnosed with LEMS.

CASE PRESENTATION

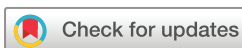A 62-year-old woman with a history of over 50 pack-years of smoking was admitted with dyspnoea. Two weeks prior to hospitalisation, she was evaluated for overall discomfort and progressive symptoms of a dry mouth and eyes and increasing difficulty with ambulation since 8 weeks. On examination, she had a notably dry oral mucosa, without any other abnormalities, especially no dyspnoea. Her pupils were equal and reactive to light. Standard laboratory workup, including a venous blood gas, was normal. Sjögren's syndrome was suspected.

Two weeks later, she returned with progressive dyspnoea. She now was clearly dyspneic with an oxygen saturation of 90%. Results of routine laboratory testing are listed in [table 1](#). Chest X-ray showed signs of pneumonia and she was admitted at the pulmonology ward.

The next day she suffered an in-hospital cardiac arrest based on hypoxia, which was attributed to sputum stasis. Beforehand, it was reported that the patient was too weak to cough up sputum herself. A significant amount of sputum was removed during bronchoscopic suctioning. Return of spontaneous circulation was achieved after 8 min of resuscitation. Subsequently, she was sedated and intubated. Sedation was terminated the next day, however, she did not trigger on the ventilator afterwards and was severely hypercapnic. Therefore, the neurology was consulted.

Neurological examination

The patient was intubated and had a Glasgow Coma Scale score of E3M6Vtube. On request, she could briefly and marginally open her eyes. She could adequately communicate by weak nodding/headshaking. Both pupils were wide (7–8 mm), fixed and mildly



© Author(s) (or their employer(s)) 2023. Re-use permitted under CC BY-NC. No commercial re-use. See rights and permissions. Published by BMJ.

Department of neurology, Canisius Wilhelmina Hospital, Nijmegen, The Netherlands

Correspondence to
Michelle FM ten Brinck;
m.tenbrinck@cwz.nl

Table 1 Laboratory results

	Normal: Value at hospitalisation <i>Italic: Two weeks prior to hospitalisation.</i> <u>Underline: During work-up</u>	Unit of measurement
Laboratory results		
Leucocytes	12.6 (8.5)	$\times 10^9/L$
Sodium	119 (139)	mmol/L
C-reactive protein	6 (7)	mg/L
Voltage-gated calcium channel antibodies	<u>0.045</u>	nmol/L
Acetylcholine receptor antibodies	<u>0.57</u>	nmol/L
Arterial blood gas		
pH	7.46	
pCO ₂	41	mm Hg
Bicarbonate	29	mmol/L
Base excess	5	mmol/L
pO ₂	60	mm Hg
Underlined: during workup.		

deformed (Online supplemental file 1). For detailed information regarding the course of the state of the pupils, see online supplemental file 2. She had hypotonia of all extremities with muscle weakness in arms and legs (Medical Research Council (MRC) scale grade 1 proximally, MRC 4 distally) and absent tendon reflexes with indifferent plantar responses.

Diagnostic workup

There was a high suspicion of LEMS because of the triad of autonomic disorders, proximal muscle weakness and areflexia. Cerebral MRI excluded an intracranial cause (specifically no brain ischaemia or central pontine myelinolysis).

Nerve conduction studies (day 3 after cardiac arrest) showed normal sensory nerve action potential amplitudes with normal nerve conduction velocities and an extreme low compound motor action potential (CMAP), peak to peak amplitude of the ulnar nerve and median nerve (<1.0mV), with normal distal motor latencies. Additionally, repetitive nerve stimulation (RNS) was performed of the ulnar nerve, facial nerve and accessory nerve, but there was no decremental response after low frequent stimulation (3 Hz, during 2 s). After maximum voluntary contraction during 30 s and after high rate stimulation (20 Hz during 2 s), no incremental response of the CMAP amplitude was measured. Needle myographic study showed myopathic motor unit action potentials. Despite not (yet) meeting the electrophysiological criteria for LEMS, suspicion remained high because of the characteristic clinical

R Ampl (mV) over Study

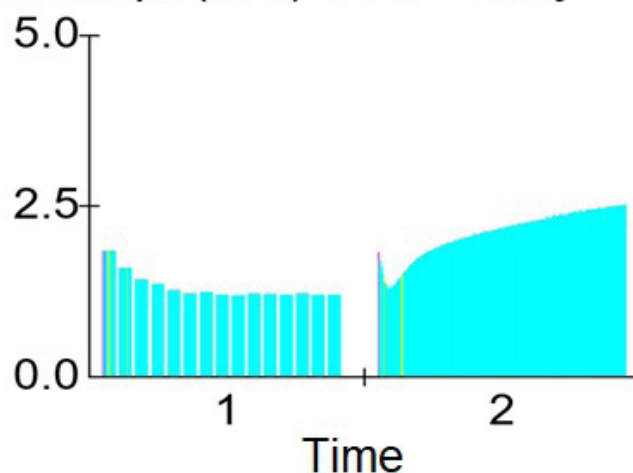


Figure 1 (1) Low frequent (3 Hz) 5 s stimulation; (2) high frequent (20 Hz) 10 s stimulation.

triad.⁷ Serum was tested for anti voltage-gated calcium channel (VGCC) antibodies, -acetylcholine receptor antibodies, -GQ1B and anti-Hu, anti-Yo, anti-Ri, anti-CV2, amphiphysin and Ma1/2 antibodies.

Further course

Treatment with 3,4-diaminopyridine, four times 20 mg daily and IVIg, was initiated. Initially, this led to an increase of muscle strength (proximally an MRC 3 and distally MRC 5), but she still required ventilation. Eventually, her pupils became smaller and responsive to light again. Six days after the first investigation, electrophysiological testing of the ulnar nerve was repeated. With low frequent stimulation (3 Hz, 5 s) a decremental response of >30% (31.2%) was recorded. During 10 s of high frequent stimulation (20 Hz), a decremental response was seen initially followed by an incremental response of >100% (66% increment compared with the first CMAP amplitude, 150% increment compared with the lowest CMAP amplitude, figure 1). These results, together with the low CMAP amplitude found at the first NCS, supported the diagnosis LEMS.⁸ Shortly after, the patient tested positive for VGCC antibodies (0.045 nmol/L (reference <0.040 nmol/L)).

A paraneoplastic form of LEMS was suspected due to a Delta-P score of 4, correlating with a high chance of (occult) small-cell lung carcinoma (SCLC).⁷ However, a conventional chest CT with intravenous contrast was negative for lung carcinoma. Additional positron emission tomography CT (PET-CT) showed a small but clear intrapulmonary FDG-avid lesion with a pathologically active node, highly suspicious for SCLC. Meanwhile, after 4 weeks of continuous improvement, muscle strength deteriorated to MRC 1 proximally. High-dose prednisone and plasmapheresis were started without result. Biopsy and treatment options were discussed with the patient, but she refused further diagnostic and therapeutic procedures and passed away after extubation.

DISCUSSION

We presented a patient, who was diagnosed at the intensive care unit with LEMS.

Developing severe respiratory failure is rare in LEMS.^{1 2 9 10} It has been observed that respiratory failure induced by anaesthesia can occur in LEMS patients and that the risk for development of prolonged muscle weakness or postoperative respiratory failure after being exposed to neuromuscular blocking agents is increasing in patients with undiagnosed or untreated LEMS.^{2 11} Rocuronium, used for intubation, may have contributed to clinical deterioration in our patient, as LEMS patients have an increased sensitivity to neuromuscular blocking drugs.¹¹ However, we feel that the prolonged generalised weakness could not be attributed to a single dose of rocuronium only.

Autonomic dysfunction is part of the classical triad of LEMS, however, when encountering fixed dilated pupils in an otherwise awake patient, LEMS is usually not considered.^{5 6}

The diameter of the pupil is a result of the balance between constriction and dilatation function. Sympathetic nerve stimulation causes pupillary dilatation.¹² The pupil constricts as a reflex in response to light and accommodation and as result of parasympathetic activation. The neurons of the Edinger-Westphal nucleus form the parasympathetic fibres of the third cranial nerve, which synapses in the ciliary ganglion. The ciliary ganglion sends postganglionic axons which innervate the sphincter pupillae muscle as well as the ciliary muscles.^{13 14} Pupil abnormalities in LEMS are thought to be a result of (pupillary) autonomic dysfunction. The return of pupillary light reflexes following administration of 3,4-diaminopyridine supports the hypothesis that the pathophysiological mechanism of autonomic dysfunction in LEMS is similar to that of the muscle weakness and relates to antibody-mediated inhibition of neurotransmitter release in cholinergic autonomic synapses.³

(Non-reactive) mydriasis after rocuronium infusion has been reported in literature.^{15–18} However, this encompasses cases with continuous infusion for a prolonged time. In these studies, mydriasis was observed within a range of 8–156 hours after start of continuous infusion. Pupillary response normalised within 12–36 hours after discontinuation. Short-term administration of neuromuscular blocking agents has been shown to have no effect on pupil size.^{18 19}

In cases of rapid sequence intubation (which also applied to our patient), a case series did not find altered pupillary response after administration of rocuronium.¹⁹

The patient had a normal renal function. Altogether, we deem it highly unlikely that the wide, fixated pupils could be attributed to the rocuronium (alone) and rather were a result autonomic dysfunction in the setting of LEMS. There was no relevant topical application of pharmacological agents that could have caused the mydriasis.

During the first electrophysiological study, our patient contracted during 30s before repeating the

measurements and we did not find an incremental response. In practice, voluntary contraction ranges from 10 to 30s, however, a significantly higher diagnostic sensitivity after 10s contraction compared with 30s exercise has been described.²⁰ Regarding high frequent RNS, it has been reported that the most severe form of LEMS results in an electrophysiological pattern with an initial decremental response at high frequent RNS followed by an incremental response (type 3 response according to Oh).⁸ Therefore, it is important to stimulate long enough (in our patient 10s) to see this incremental response.

Our patient had relatively low anti-VGCC antibodies (0.045 nmol/L). Elevated antibodies against VGCC without corresponding clinical symptoms are not specific for LEMS and should be interpreted with caution.^{21 22} Furthermore, studies did not show a correlation between extent of disease, survival and levels of serum anti-VGCC.²³

The presence of VGCC-antibodies combined with the classic clinical triad including wide fixed pupils, respiratory failure and the electrophysiological results confirmed the diagnosis of LEMS in our patient.

Highlights

- ⇒ A rare course of Lambert-Eaton myasthenic syndrome, with early respiratory failure and wide, fixed pupils.
- ⇒ It is important to stimulate long enough to see the incremental response with repetitive nerve stimulation.
- ⇒ Emphasises the importance of malignancy screening with PET-CT when there is a high suspicion of small-cell lung carcinoma with negative conventional CT.

Contributors MTB and IWHV: collect data, authors of the manuscript. JvdW and GWvd: supervising the work, clinically involved and revision of the manuscript. FAPN: involved in the electrophysiological part, writing part of the manuscript and revision. AV: critical revision of the work.

Funding The authors have not declared a specific grant for this research from any funding agency in the public, commercial or not-for-profit sectors.

Competing interests None declared.

Patient consent for publication Consent obtained from next of kin.

Provenance and peer review Not commissioned; externally peer reviewed.

Data availability statement Data are available on reasonable request.

Supplemental material This content has been supplied by the author(s). It has not been vetted by BMJ Publishing Group Limited (BMJ) and may not have been peer-reviewed. Any opinions or recommendations discussed are solely those of the author(s) and are not endorsed by BMJ. BMJ disclaims all liability and responsibility arising from any reliance placed on the content. Where the content includes any translated material, BMJ does not warrant the accuracy and reliability of the translations (including but not limited to local regulations, clinical guidelines, terminology, drug names and drug dosages), and is not responsible for any error and/or omissions arising from translation and adaptation or otherwise.

Open access This is an open access article distributed in accordance with the Creative Commons Attribution Non Commercial (CC BY-NC 4.0) license, which permits others to distribute, remix, adapt, build upon this work non-commercially, and license their derivative works on different terms, provided the original work is properly cited, appropriate credit is given, any changes made indicated, and the use is non-commercial. See: <http://creativecommons.org/licenses/by-nc/4.0/>.

ORCID iD

Michelle FM ten Brinck <http://orcid.org/0000-0003-1298-9322>

REFERENCES

- 1 Smith AG, Wald J. Acute ventilatory failure in Lambert-Eaton Myasthenic syndrome and its response to 3,4-diaminopyridine. *Neurology* 1996;46:1143–5.
- 2 O'Neill JH, Murray NM, Newsom-Davis J. The Lambert-Eaton Myasthenic syndrome. A review of 50 cases. *Brain* 1988;577–96.
- 3 Wirtz PW, de Keizer RJ, de Visser M, et al. Tonic pupils in Lambert-Eaton Myasthenic syndrome. *Muscle Nerve* 2001;24:444–5.
- 4 Meys VEWH, Koehler PJ. Alert patients with mydriasis and fixed pupils. *Ned Tijdschr Geneeskd* 2014;157:A6581.
- 5 Thomas PD. The differential diagnosis of fixed dilated pupils: a case report and review. *Crit Care Resusc* 2000;2:34–7.
- 6 Cordova S, Lee R. Fixed, dilated pupils in the ICU: another recoverable cause. *Anaesth Intensive Care* 2000;28:91–3.
- 7 Titulaer MJ, Maddison P, Sont JK, et al. Clinical Dutch-English Lambert-Eaton Myasthenic syndrome (LEMS) tumor association prediction score accurately predicts small-cell lung cancer in the LEMS. *J Clin Oncol* 2011;29:902–8.
- 8 Oh SJ. Diverse electrophysiological spectrum of the Lambert-Eaton Myasthenic syndrome. *Muscle Nerve* 1989;12:464–9.
- 9 Brueck M, Vogel S, Waeger S, et al. Lambert-Eaton Myasthenic syndrome with acute respiratory failure associated with small cell lung cancer. *Dtsch Med Wochenschr* 2004;129:193–6.
- 10 Jiang J-R, Shih J-Y, Wang H-C, et al. Small-cell lung cancer presenting with Lambert-Eaton Myasthenic syndrome and respiratory failure. *J Formos Med Assoc* 2002;101:871–4.
- 11 Weingarten TN, Araka CN, Mogensen ME, et al. Lambert-Eaton Myasthenic syndrome during anesthesia: a report of 37 patients. *J Clin Anesth* 2014;26:648–53.
- 12 Clark CV, Newsom-Davis J, Sanders MD. Ocular autonomic nerve function in Lambert-Eaton Myasthenic syndrome. *Eye (Lond)* 1990;4:473–81.
- 13 Belliveau AP, Somani AN, Dossani RH. Pupillary light reflex. In: *StatPearls*. Treasure Island (FL): StatPearls Publishing LLC, 2023.
- 14 Bouffard MA. The pupil. *Continuum (Minneapolis)* 2019;25:1194–214.
- 15 Zakyntinos GE, Tsolaki V, Bardaka F, et al. Fixed dilated pupils in COVID-19 ARDS patients under rocuronium, reversed after discontinuation. *J Crit Care* 2021;65:259–60.
- 16 Fernandes FA, Pontes JPJ, Borges CER, et al. Non-reactive mydriasis after rocuronium infusion in patients with COVID-19: a case series. *Braz J Anesthesiol* 2022;72:829–31.
- 17 He H, Yu Z, Zhang J, et al. Bilateral dilated nonreactive pupils secondary to rocuronium infusion in an ARDS patient treated with ECMO therapy: a case report. *Medicine* 2020;99:e21819.
- 18 Schmidt JE, Tamburro RF, Hoffman GM. Dilated nonreactive pupils secondary to neuromuscular blockade. *Anesthesiology* 2000;92:1476–80.
- 19 Gray AT, Krejci ST, Larson MD. Neuromuscular blocking drugs do not alter the pupillary light reflex of anesthetized humans. *Arch Neurol* 1997;54:579–84.
- 20 Hatanaka Y, Oh SJ. Ten-second exercise is superior to 30-second exercise for post-exercise facilitation in diagnosing Lambert-Eaton Myasthenic syndrome. *Muscle Nerve* 2008;37:572–5.
- 21 Abboud H, Rossman I, Mealy MA, et al. Neuronal autoantibodies: differentiating clinically relevant and clinically irrelevant results. *J Neurol* 2017;264:2284–92.
- 22 Di Lorenzo R, Mente K, Li J, et al. Low specificity of voltage-gated calcium channel antibodies in Lambert-Eaton Myasthenic syndrome: a call for caution. *J Neurol* 2018;265:2114–9.
- 23 Payne M, Bradbury P, Lang B, et al. Prospective study into the incidence of Lambert Eaton Myasthenic syndrome in small cell lung cancer. *J Thorac Oncol* 2010;5:34–8.