

Autoimmune glial fibrillary acidic protein astrocytopathy presented as ataxia, myoclonus and bulbar syndrome: a case report and review of the literature

Azael C Novo , Begoña Venegas Pérez

To cite: C Novo A, Venegas Pérez B. Autoimmune glial fibrillary acidic protein astrocytopathy presented as ataxia, myoclonus and bulbar syndrome: a case report and review of the literature. *BMJ Neurology Open* 2021;**3**:e000142. doi:10.1136/bmjno-2021-000142

► Additional supplemental material is published online only. To view, please visit the journal online (<http://dx.doi.org/10.1136/bmjno-2021-000142>).

Accepted 25 August 2021

ABSTRACT

Objective To describe an atypical case of autoimmune glial fibrillary acidic protein (GFAP) astrocytopathy.

Results A patient in his 60s presented with 6 months of progressive ataxia, proximal myoclonus and bulbar symptomatology. Cerebrospinal fluid (CSF) analysis showed monocytic pleocytosis, elevated protein level and elevated adenosine deaminase (ADA) level. CSF microbiological studies were negative and brain and cervical MRI showed no significant findings. We tested for nuclear, cytoplasmatic and synaptic neural autoantibodies as well as anti-GFAP antibodies. While awaiting these results, the patient was commenced on methylprednisolone boluses (1 g/day for 5 days), noting rapid neurological improvement. Eventually, CSF tests were positive for anti-GFAP antibodies.

Conclusion We report atypical manifestations of GFAP astrocytopathy. Further research is needed to fully understand the spectrum of neurological manifestations of this autoimmune disease and facilitate timely diagnosis.

INTRODUCTION

Autoimmune glial fibrillary acidic protein (GFAP) astrocytopathy was first defined in 2016.¹ The most reported manifestations of this autoimmune disease are fever, headache, convulsions, delirium, meningism and loss of visual acuity.² Brain and spinal cord MRI generally show inflammatory lesions and cerebrospinal fluid (CSF) analysis also reveals inflammatory parameters.² However, there are cases of atypical manifestations. Here we report a case of a patient with GFAP astrocytopathy who presented with chronic progressive ataxia, myoclonus and bulbar symptomatology.

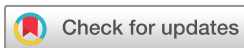CASE REVIEW

A patient in his 60s presented with 6 months of progressive hypophonia, hyporexia, weight loss, gait instability and dysphagia for solids. Neurological assessment showed ataxia, proximal myoclonus in the four extremities, general amyotrophy with proximal

tetraparesis and normal osteotendinous reflexes. No optic fundi examination was performed. Blood tests including haemogram, serum biochemistry, tumour markers (alpha-fetoprotein, CA-15.2, CA-19.9, CA125 and carcinoembryonic antigen (CEA)) and serum microbiological studies (syphilis, HIV and *Borrelia burgdorferi* serologies) were normal. Neuroimaging studies (brain and cervical MRI without contrast; online supplemental figures 1–5) showed no significant findings. Nerve conduction and electromyography revealed chronic neurogenic changes affecting the bulbar muscles as well as the four extremities, but no acute disorders. Suspecting a vermian syndrome, we tested for spinocerebellar ataxias, with normal results. The patient was discharged from hospital expecting a follow-up consultation in the upcoming months.

However, a few weeks later the patient was referred once again to our hospital. He presented with worse gait instability, sphincter incontinence, severe cognitive impairment, vertical conjugated gaze palsy and oculomotor signs of cerebellar disfunction (hypermetric ocular saccades). No optic fundi examination could be performed this time because of the patient's lack of collaboration. Autoimmunity tests (anti-transglutaminase IgA antibodies, ACE and nuclear and cytoplasmatic neural antibodies (Hu, Yo, Ri, CV2, amphiphysin, Ma2/Ta, Tr, SOX1, Zic4, GAD65, recoverin and titin; see [table 1](#))) were negative. Tests for vitamins A and E were also negative, as well as tuberculosis and *Tropheryma whippelli* studies. Electroencephalography showed background brain activity slowing and sporadic diffuse triphasic waves in intervals up to 1–2s slightly predominant on the right hemisphere; these discharges lasted up to 8s ([figure 1](#)).

CSF analysis showed monocytic pleocytosis, elevated protein level and elevated adenosine



© Author(s) (or their employer(s)) 2021. Re-use permitted under CC BY-NC. No commercial re-use. See rights and permissions. Published by BMJ.

Department of Neurology, Hospital Universitario de Cabueñes, Gijón, Spain

Correspondence to

Dr Azael C Novo; azael.cordero@sespa.es

Table 1 Blood and CSF tests for autoimmune diseases

Requested analysis	Results
Anti-transglutaminase (blood)	Negative
Ant-IgA (blood)	Negative
ACE (blood)	Below determination threshold
Anti-Hu (blood)	Negative
Anti-Yo (blood)	Negative
Anti-Ri (blood)	Negative
Anti-CV2 (blood)	Negative
Anti.amphiphysin (blood)	Negative
Anti-Ma2/Ta (blood)	Negative
Anti-Tr (blood)	Negative
Anti-SOX1 (blood)	Negative
Anti-Zic4 (blood)	Negative
Anti-GAD65 (blood)	Negative
Anti-recoverin (blood)	Negative
Anti-titin (blood)	Negative
Anti-NMDAR (CSF)	Negative
Anti-AMPA (CSF)	Negative
Anti-GABABR (CSF)	Negative
Anti-LGI1 (CSF)	Negative
Anti-CASPR2 (CSF)	Negative
Anti-DPPX (CSF)	Negative
Anti-MGLUR-1 (CSF)	Negative
Anti-MGLUR-5 (CSF)	Negative
Anti-GFAP (CSF)	Positive (by immunoreactivity tests, confirmed with cell-based assay (CBA))

ADA, adenosine deaminase; AMPAR, anti-alpha-amino-3-hydroxy-5-methyl-4-isoxazolepropionic acid receptor; CASPR2, conectin-associated protein 2; CSF, cerebrospinal fluid; DPPX, dipeptidyl-peptidase-like protein 6; GABABR, gamma-aminobutyric acid type B receptor; GFAP, glial fibrillary acidic protein; LGI1, leucine-rich glioma-inactivated 1; MGLUR-1, metabotropic glutamate receptor 1; MGLUR-5, metabotropic glutamate receptor 5; NMDAR, N-methyl-D-aspartic receptor.

deaminase level (see table 2). Anatomopathological and microbiological studies were normal. Protein 14.3.3 was negative. We tested for synaptic neural autoantibodies (N-methyl-D-aspartic receptor (NMDAR), anti-alpha-amino-3-hydroxy-5-methyl-4-isoxazolepropionic acid

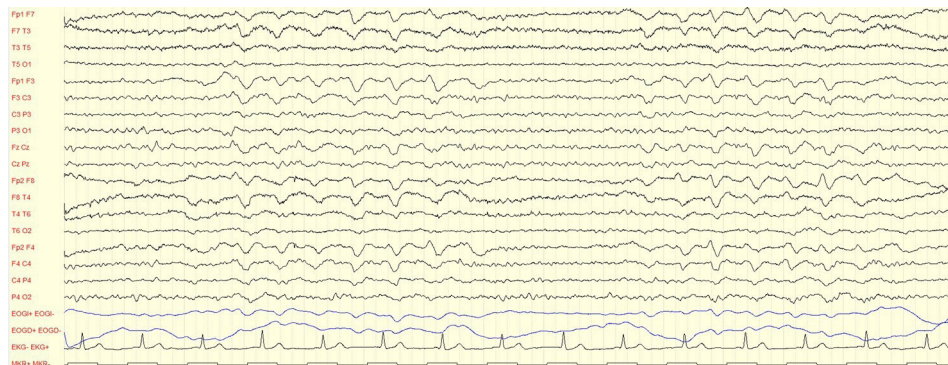
Table 2 CSF characteristics before and after intravenous methylprednisolone boluses (1g/day for 5 days)

CSF characteristics	Before corticosteroid treatment (day 23 of hospitalisation)	1 week after corticosteroid treatment (day 35 of hospitalisation)
Appearance	Clear	Clear
Leucocytes/mm ³	120	46
Monocytes (%)	98	91
Polymorphonuclears (%)	2	9
Red blood cells/mm ³	3	2400*
Glucose (mg/dL)	51	55
Proteins (g/L)	1.25	0.53
ADA (U/L)	13.7	9.5
Oligoclonal bands	8 IgG bands	Not determined

*Traumatic puncture. CSF, cerebrospinal fluid.

receptor (AMPA), gamma-aminobutyric acid type B receptor (GABABR), leucine-rich glioma-inactivated 1 (LGI1), contactin-associated protein 2 (CASPR2), dipeptidyl-peptidase-like protein 6 (DPPX), metabotropic glutamate receptor 1 (MGLUR-1) and metabotropic glutamate receptor 5 (MGLUR-5)) as well as anti-GFAP antibodies in CSF, suspecting an autoimmune neurological disease. Gastroscopy, body CT and body positron emission tomography-CT exclude neoplasms.

While awaiting neural autoantibodies results, by day 23 of hospitalisation, the patient was given intravenous methylprednisolone boluses (1g/day for 5 days), noting great clinical and functional improvement as well as normalisation of the inflammatory parameters in CSF (see table 1). The patient was able to ambulate with assistance, myoclonus ceased, and the abnormal ocular saccades and the vertical conjugated gaze palsy disappeared. Cognitive impairment also improved significantly, for the patient was now oriented in space and time. Nevertheless, tetraparesis and dysphagia persisted.

**Figure 1** Electroencephalography of the patient showing background brain activity slowing and sporadic diffuse triphasic waves in intervals up to 1-2s, slightly predominant on the right hemisphere.

The patient was discharged from hospital after receiving physiotherapy treatment, still in need of dysphagia-oriented diet and ambulation assistance. CSF test results for neural autoantibodies were still unknown at this time and they were to be checked in a follow-up consultation. No chronic treatment was then commenced.

Nevertheless, the patient died days later, suspecting bronchial aspiration as the cause of death. Anatomopathological studies couldn't be performed to confirm the suspicion of an autoimmune neurological disease. However, we obtained positive CSF tests results for anti-GFAP antibodies (by immunoreactivity tests and confirmation with cell-based assay (CBA); no titres informed). Finally, the patient was diagnosed with autoimmune GFAP astrocytopathy despite the lack of anatomopathological studies.

DISCUSSION

GFAP is the main intermediate filament protein in mature astrocytes and a component of their cytoskeleton. It is the main target of autoimmune GFAP astrocytopathy,¹ a disease with a physiopathology which remains poorly understood. This type of autoimmune disease was first defined through the discovery of GFAP-IgG antibodies, using different methods such as immunofluorescence assay, CBA or western blot.¹ However, this disease is hypothesised to be caused by a cytotoxic response mediated by T cells; therefore, GFAP-IgGs would be neural autoantibody intermediaries in the autoimmune response, since GFAP is an intracellular antigen.²

Autoimmune GFAP astrocytopathy is associated with other autoimmune disorders like type 1 diabetes, Graves's thyroiditis or even autoimmune encephalitis, such as anti-N-methyl-D-aspartic acid encephalitis.^{1 2} In addition to this, autoimmune GFAP astrocytopathy is a paraneoplastic phenomenon in a third of the patients, and ovarian teratoma is the most commonly found neoplasm.³

According to the most recent studies, consisting mostly of case reports and case series, the median age of onset of autoimmune GFAP astrocytopathy is 40–50 years^{4 5} (range 8–103)⁴. No gender predilection has been reported.² Clinically, autoimmune GFAP astrocytopathy usually presents as an acute disorder,⁶ although there are unusual cases of subacute or even chronic presentation.⁵ A history of symptoms of upper respiratory tract infection is found in 40% of the cases.² The most common manifestations include headache, abnormal vision, ataxia, altered consciousness, myelitis and seizures.^{5 7 8} Movement disorders and neuropsychiatric alterations are less frequent;^{4 9} bulbar syndrome,⁷ sensorimotor neuropathy⁶ or bilateral sensorineural hearing loss¹⁰ are even more uncommon. Syndromes are often defined as encephalitis, meningoencephalitis, myelitis or their combinations. Some of the demographic data, symptoms and clinical syndromes reported in the most recent literature can be found in the online supplemental table 1.^{1 4–8 10 11}

Inflammatory parameters are usually found in CSF (monocytic pleocytosis, elevated protein level and low glucose level). Brain and spinal cord MRI usually show non-specific findings such as T2-hyperintense lesions, gadolinium-enhanced lesions in T1 sequences, and even leptomeningeal enhancement.² Nevertheless, neuroimaging studies show no alterations in half of the patients.⁷

For acute treatment, patients are usually given intravenous methylprednisolone boluses (0.5–1 g/day for 5 days), with great clinical improvement.² However, intravenous immunoglobulins or plasma exchange is sometimes necessary to achieve disease remission.⁵ Chronic immunosuppressive therapy, with mycophenolate mofetil, azathioprine or rituximab, is required in 20%–50% of the cases to prevent relapses.² Prognosis is usually favourable;⁶ however, it is worse in some case series⁸ due to unknown causes, but the time of disease progression might contribute as an important factor. More information on these topics can be found in the online supplemental table 1.^{1 4–8 10 11}

Considering all the above-mentioned data, we report an atypical case of autoimmune GFAP astrocytopathy bearing in mind both its initial clinical progression and manifestations. Chronic progression of autoimmune GFAP astrocytopathy, as in our patient (6 months), is an unusual finding, and only a few patients having disease progression for months have been reported previously.⁸ Moreover, our patient only presented for these 6 months ataxia, bulbar symptomatology (with predominance of dysphagia) and myoclonus. More frequent manifestations such as headache, loss of visual acuity, seizures or myelitis were not present. Bulbar symptomatology, to our knowledge, has been reported only twice,^{1 7} and dysphagia has been described only in one case.¹ Some case series have also described movement disorders⁷ and dyskinesias,⁵ but we have found only one case specifically reporting myoclonus as in our patient.¹¹ Cognitive disturbances, which are typical symptoms according to the literature,^{4 5 7 9} appeared only weeks after first hospitalisation in our patient, approximately after 7–8 months of disease progression. Moreover, hypermetric ocular saccades were noted during the second hospitalisation. It is our belief that this is the first time this neurological finding is reported in autoimmune GFAP astrocytopathy. In addition to this, no upper tract respiratory symptoms were reported in our case, neuroimaging studies showed no lesions and we could not find any signs of neoplasms.

However, and consistently with other studies, our patient did have both inflammatory parameters in CSF (monocytic pleocytosis and elevated protein level) and showed great clinical improvement when given corticosteroid treatment. Nevertheless, we suspect that the patient was given this therapy too late, delay caused by the uncommon manifestations of autoimmune GFAP astrocytopathy found in our patient, provoking secondary functional deterioration. This may have contributed to the patient's decease after he was finally discharged from hospital.



In summary, we report new, atypical manifestations of autoimmune GFAP astrocytopathy, to facilitate the early recognition of this disease and prevent neurological and functional deterioration due to its progression. Autoimmune GFAP astrocytopathy should be considered in the differential diagnosis of patients presenting with manifestations as the ones described in this paper. Further research is necessary to know the full spectrum of manifestations of this recently defined autoimmune neurological disease.

Twitter Azael C Novo @leaza94

Acknowledgements The authors thank Marta Vázquez Pérez for her continuous help and guidance throughout the translation and proofreading of this manuscript.

Contributors ACN: writing of the manuscript. ACN and BVP: clinical review of the patient and revision of the manuscript.

Funding The authors have not declared a specific grant for this research from any funding agency in the public, commercial or not-for-profit sectors.

Competing interests None declared.

Patient consent for publication Not applicable.

Provenance and peer review Not commissioned; externally peer reviewed.

Data availability statement Data sharing not applicable as no data sets generated and/or analysed for this study. Not applicable.

Supplemental material This content has been supplied by the author(s). It has not been vetted by BMJ Publishing Group Limited (BMJ) and may not have been peer-reviewed. Any opinions or recommendations discussed are solely those of the author(s) and are not endorsed by BMJ. BMJ disclaims all liability and responsibility arising from any reliance placed on the content. Where the content includes any translated material, BMJ does not warrant the accuracy and reliability of the translations (including but not limited to local regulations, clinical guidelines, terminology, drug names and drug dosages), and is not responsible for any error and/or omissions arising from translation and adaptation or otherwise.

Open access This is an open access article distributed in accordance with the Creative Commons Attribution Non Commercial (CC BY-NC 4.0) license, which

permits others to distribute, remix, adapt, build upon this work non-commercially, and license their derivative works on different terms, provided the original work is properly cited, appropriate credit is given, any changes made indicated, and the use is non-commercial. See: <http://creativecommons.org/licenses/by-nc/4.0/>.

ORCID ID

Azael C Novo <http://orcid.org/0000-0002-6012-0990>

REFERENCES

- 1 Fang B, McKeon A, Hinson SR, *et al*. Autoimmune glial fibrillary acidic protein astrocytopathy: a novel meningoencephalomyelitis. *JAMA Neurol* 2016;73:1297–307.
- 2 Kunchok A, Zekeridou A, McKeon A. Autoimmune glial fibrillary acidic protein astrocytopathy. *Curr Opin Neurol* 2019;32:452–8.
- 3 Zarkali A, Cousins O, Athauda D, *et al*. Glial fibrillary acidic protein antibody-positive meningoencephalomyelitis. *Pract Neurol* 2018;18:315–9.
- 4 Flanagan EP, Hinson SR, Lennon VA, *et al*. Glial fibrillary acidic protein immunoglobulin G as biomarker of autoimmune astrocytopathy: analysis of 102 patients. *Ann Neurol* 2017;81:298–309.
- 5 Long Y, Liang J, Xu H, *et al*. Autoimmune glial fibrillary acidic protein astrocytopathy in Chinese patients: a retrospective study. *Eur J Neurol* 2018;25:477–83.
- 6 Allen A, Gulhar S, Haidari R, *et al*. Autoimmune glial fibrillary acidic protein astrocytopathy resulting in treatment-refractory flaccid paralysis. *Mult Scler Relat Disord* 2020;39:101924.
- 7 Iorio R, Damato V, Evoli A, *et al*. Clinical and immunological characteristics of the spectrum of GFAP autoimmunity: a case series of 22 patients. *J Neurol Neurosurg Psychiatry* 2018;89:138–46.
- 8 Yang X, Liang J, Huang Q, *et al*. Treatment of autoimmune glial fibrillary acidic protein astrocytopathy: follow-up in 7 cases. *Neuroimmunomodulation* 2017;24:113–9.
- 9 Shan F, Long Y, Qiu W. Autoimmune glial fibrillary acidic protein astrocytopathy: a review of the literature. *Front Immunol* 2018;9:2802.
- 10 Ip B, Lam C, Ip V, *et al*. Autoimmune glial fibrillary acidic protein astrocytopathy associated meningoencephalomyelitis and bilateral sensorineuronal deafness. *Mult Scler Relat Disord* 2020;40:101922.
- 11 Lee PKJ, Small JE, Vytöpil M. Teaching NeuroImages: autoimmune glial fibrillary acidic protein meningoencephalomyelitis. *Neurology* 2019;93:e2076–7.